

Research article

How to Edit a Manuscript with Assistance of ChatGPT

Nghi V Tran^{1,*}, **Doan Ngoc Chau Nguyen**², **Duc H Nguyen**³, **Hien Q Nguyen**³, **Van Tuong Nguyen**³, **Huong Trinh**³, **Thien Pham**³, **Nam Pham**⁴, **Tu Nguyen**⁴, **Loc T Vu**⁴, **Thinh Nguyen**³, **Thang Nguyen**³, **Dien T Nguyen**⁵, **Thach Nguyen**^{3,5}

¹ Department of Medicine, Louis A. Weiss Memorial Hospital, Chicago, IL, USA

² Texas Tech University-HSC at Amarillo, Amarillo, TX, USA

³ Cardiovascular Research Department, Methodist Hospital, Merrillville, IN USA

⁴ University of Medicine and Pharmacy at Ho Chi Minh City, Ho Chi Minh City, Vietnam

⁵ Tan Tao University, School of Medicine, Long An Province, Vietnam

*Corresponding author:

Nghi V Tran, MD

Department of Medicine, Louis A. Weiss Memorial Hospital, Chicago, IL, USA

Email: tranvietnghi2007@gmail.com

Article history: Manuscript received March 20, 2023; revised manuscript received May 22, 2023; accepted May 26, 2023.

ABSTRACT

This research article investigates the efficacy of ChatGPT, an AI-based language model developed by OpenAI, as a manuscript editing tool. The study's design and methodology used to evaluate ChatGPT's usefulness in editing are described, and a detailed analysis of the study results is presented, highlighting ChatGPT's strengths and weaknesses in manuscript editing. The literature review establishes the importance of manuscript editing and the challenges associated with traditional editing methods while also discussing the advantages of AI-based editing tools. While previous studies have shown the potential benefits of AI technology in manuscript editing, further research is needed to investigate more complex issues and cultural nuances. This research article adds to the growing literature on the use of AI in manuscript editing, providing valuable insights into ChatGPT's benefits and limitations as an editing tool for authors. By improving the quality of the work, providing constructive feedback, and streamlining the editing process, ChatGPT can aid authors in producing high-quality work more efficiently.

KEYWORDS ChatGPT, Manuscript editing, AI-based language model, Natural Language Processing (NLP), Editing process, Grammar correction, Coherence correction, AI-based editing tools, Automated assistance, Readability, Ethical implications.

INTRODUCTION

Editing is crucial in manuscript preparation and significantly enhances the quality of written work. Effective editing improves clarity, coherence, and readability, making engaging readers with the content easier. Moreover, it helps identify and correct grammar, punctuation, and spelling errors, which can detract from the work's overall quality. Ultimately, editing results in a polished manuscript ready for publication and dissemination to a broader audience. Access to reliable and efficient editing tools is critical for authors to produce high-quality work.

ChatGPT is an artificial intelligence (AI)-based language

model developed by OpenAI that has the ability to generate human-like text. Its capabilities extend beyond generating text to also include assisting authors in the editing process. Using natural language processing (NLP) algorithms, ChatGPT can analyze and provide feedback on the coherence, grammar, syntax, and structure of a manuscript. It can also suggest improvements to sentence structure and provide alternative word choices to improve the overall quality of the work. ChatGPT can work collaboratively with authors to refine their writing, providing suggestions that authors can accept, reject, or modify as they see fit. In this way, ChatGPT is a powerful tool that can help authors streamline the

manuscript editing process and produce high-quality work more efficiently.

The primary goal of this research article is to explore the use of ChatGPT in manuscript editing and evaluate its effectiveness. The article will describe the study design and methodology used to assess the usefulness of ChatGPT in the manuscript editing process. It will also provide a detailed analysis of the results obtained from the study, highlighting the strengths and weaknesses of ChatGPT in manuscript editing. Ultimately, the article will demonstrate how ChatGPT can assist authors in editing their manuscripts by streamlining the editing process, providing constructive feedback, and improving the overall quality of the work. The research presented in this article will contribute to the growing body of literature on the use of AI in manuscript editing and provide valuable insights into the potential benefits and limitations of ChatGPT as an editing tool for authors.

PERSPECTIVES

Knowledge

The study reveals that ChatGPT, an AI-based language model developed by OpenAI, can be a valuable tool for manuscript editing. ChatGPT can identify errors, suggest revisions, and improve the quality of the content. However, it is important to note that ChatGPT should not replace human editors but rather should be used as a complementary tool to support and enhance their work. Authors and editors should recognize the limitations of ChatGPT in addressing complex issues and contextual and linguistic nuances or conciseness in the content. Additionally, authors and editors must consider the potential ethical and legal consequences of using AI-based editing tools, such as data ownership, privacy, algorithmic bias, and discrimination.

Translational Outlook

Authors and editors can use ChatGPT to complement their own editing skills and work with human editors when needed. Clear guidelines for ChatGPT's use should be established, and its limitations should be taken into account. Collaboration among ChatGPT, authors, and editors is vital to maximize its effectiveness in the manuscript editing process. Furthermore, authors and editors should remain aware of the potential ethical and legal implications of using AI-based editing tools and regularly evaluate their effectiveness. By utilizing ChatGPT in the manuscript editing process, authors can improve the quality of their work and increase the likelihood of success in the publishing process.

LITERATURE REVIEW

Editing is an essential aspect of manuscript preparation, which involves reviewing, revising, and refining the written content to improve its quality and coherence [1]. The purpose of manuscript editing is to ensure that the content is clear, concise, and coherent, free from grammatical, spelling, and punctuation errors, and meets the standards of the intended audience [2]. Effective editing can help authors communicate their ideas more clearly and persuasively, improve the read-

ability and flow of the content, and ensure that the manuscript meets the submission requirements of publishers, journals, or media outlets. In addition, editing can also help to identify and address any factual, conceptual, or logical inconsistencies in the content, making the manuscript more accurate and trustworthy [3]. Overall, manuscript editing plays a crucial role in the success of the publishing process by enhancing the quality of the content and increasing its chances of being accepted for publication.

The traditional editing process involves several stages, starting with the review of the manuscript's overall structure and content, followed by a more detailed line-by-line editing for style, grammar, and punctuation. The editor may also provide feedback on the content's clarity, organization, and argumentation [4]. While this process can help to improve the quality of the manuscript, it has several limitations and challenges. For example, traditional editing methods are often time-consuming and expensive, requiring multiple rounds of revisions and reviews. Additionally, the subjective nature of editing means that there is a risk of personal bias, which may influence the editor's decisions. Furthermore, human error is always a possibility, and even experienced editors can overlook errors, leading to inconsistencies in the content. These limitations and challenges of traditional editing methods have led to the emergence of AI-based editing tools, which are becoming increasingly popular in the publishing industry.

AI technology has revolutionized many industries, including publishing. AI-based tools for manuscript editing are becoming increasingly popular due to their ability to streamline the editing process, reduce errors, and improve the overall quality of the content [5], [6]. These tools use natural language processing (NLP) and machine learning algorithms to analyze and optimize the content for grammar, style, and coherence. AI editing tools can provide real-time feedback, allowing authors to make corrections quickly and efficiently, thus saving time and reducing the cost of editing [7], [8]. Additionally, AI tools can provide consistent and unbiased feedback, unlike human editors, who may be influenced by personal preferences and biases. Moreover, AI-based editing tools can also help authors to optimize their content for specific target audiences and meet the submission requirements of different publishers, increasing the chances of publication [9], [10]. Overall, the emergence of AI technology in manuscript editing has made the process more efficient, accurate, and accessible for authors.

Previous studies have shown that AI technology can be a useful tool for manuscript editing, providing authors with automated assistance in identifying errors, suggesting revisions, and enhancing the overall quality of the content. Some of the key findings from these studies include the ability of AI tools to detect and correct grammatical and punctuation errors more accurately and quickly than human editors, as well as their capacity to analyze the structure and coherence of the content and suggest improvements in sentence construction and readability [11]-[15]. However, while the use of AI technology in manuscript editing has

shown promise, there are still some gaps in the literature and areas for further research. For instance, more research is needed to investigate the potential of AI tools in detecting and correcting more complex issues, such as contextual and stylistic errors, as well as the limitations of AI in identifying and addressing cultural and linguistic nuances in the content. In addition, there is a need to explore the ethical and social implications of using AI in manuscript editing and to develop guidelines and standards for its use. Overall, previous studies suggest that AI can be a valuable tool in manuscript editing, but further research is needed to maximize its potential and address its limitations.

METHODOLOGY

Inclusion The study will select 5 academic manuscripts from diverse studies and then extract a part from different sections of each manuscript.

Method The original versions of the 5 manuscripts will be collected, and the authors' permission will be obtained to use their manuscripts for this study. A part from different sections of each manuscript will then be edited using ChatGPT's editing features. The editing process will be conducted by a single editor to ensure consistency in the editing approach. The editor will document any difficulties encountered during the editing process. Here are the problems that we will use ChatGPT to correct:

Grammar and spelling checks: ChatGPT can scan the manuscript for grammatical errors and spelling mistakes, providing suggested corrections to improve the clarity and accuracy of the text.

Punctuation and capitalization checks: ChatGPT can also review the manuscript for punctuation and capitalization errors, providing suggested corrections to improve the manuscript's overall readability.

Style and tone suggestions: ChatGPT can analyze the tone and style of the manuscript, providing suggestions for how to improve the manuscript's overall ideas flow and structure.

Sentence restructuring and rephrasing: ChatGPT can offer suggestions for how to restructure or rephrase sentences to improve clarity and coherence, providing more concise and readable prose.

Contextual feedback: ChatGPT can provide context-specific feedback on language usage, ensuring that the manuscript is accurate and relevant to the intended audience.

Consistency checks: ChatGPT can help ensure consistency in style, language, and formatting throughout the manuscript, making it easier for readers to follow the author's argument and stay engaged.

Fact-checking: ChatGPT can help verify the accuracy of statements made in the manuscript, flagging potential inaccuracies and offering suggestions for how to correct them.

Citation and reference checks: ChatGPT can ensure that the manuscript's citations and references are accurate, consistent, and properly formatted.

Plagiarism detection: ChatGPT can scan the manuscript for potential instances of plagiarism, alerting the author to

any passages that may need to be revised or removed.

Language translation: ChatGPT can also assist authors in editing manuscripts written in languages other than their own by offering translations and suggestions for how to improve the manuscript's clarity and accuracy in the target language.

Data Collection: Data will be collected from both the original and edited versions of the manuscripts. The edited versions will be compared with the original versions to evaluate the effectiveness of ChatGPT's editing features. The edited versions will be evaluated for grammar, punctuation, spelling, syntax, and coherence. The original and edited versions will be compared using a readability index, such as the Flesch-Kincaid readability test.

Data analysis: The data collected will be analyzed using descriptive statistics, including means and standard deviations, to summarize the results of the readability index and the editing quality. The time taken for editing and the number of revisions made using ChatGPT will also be analyzed to evaluate the efficiency and effectiveness of the tool in manuscript editing.

Ethical considerations: The study will adhere to ethical guidelines for human research, including obtaining informed consent from authors whose manuscripts are used for the study. The study will ensure that the authors have the option to withdraw their manuscripts from the study at any time without penalty or consequences. The authors' personal information will be kept confidential, and any identifying information will be removed before analysis.

RESULT

In this study, we evaluated the effectiveness of using ChatGPT, an OpenAI-trained language model, as an editing tool for a manuscript. To facilitate demonstration, we only selected a section from a sample manuscript written in English that had already been successfully published, and compared the quality of that section before and after using ChatGPT for editing.

Sample 1:

This is the original version of the abstract section from the article titled "Prolonged Coronary Transit Time and Reversed Flow Causing Functional Ischemia, Chest Pain and Syncope in Patients with Aortic Stenosis and Patent Coronary Arteries: An Angiographic and Machine Learning Analysis" (Figure 1) [16].

Background. Patients afflicted with aortic stenosis (AS) may present chest pain (CP), shortness of breath (SOB), syncope, and no lesion in the coronary arteries. So far, no clear mechanism could convincingly elucidate the pathophysiology of symptoms in such patients. We conducted a study to clarify the mechanism of CP, SOB, and syncope in AS patients without coronary artery stenosis based on coronary flow patterns or abnormalities.

Methods. One hundred and thirty two (132) patients visiting the emergency room with CP, SOB, or syncope were screened for AS. Forty four (44) patients with a clinical

ABSTRACT

Background. Patients afflicted with aortic stenosis (AS) may present chest pain (CP), shortness of breath (SOB), syncope, and no lesion in the coronary arteries. So far, no clear mechanism could convincingly elucidate the pathophysiology of symptoms in such patients. We conducted a study to clarify the mechanism of CP, SOB, and syncope in AS patients without coronary artery stenosis based on coronary flow patterns or abnormalities.

Methods. One hundred and thirty two (132) patients visiting the emergency room with CP, SOB, or syncope were screened for AS. Forty four (44) patients with a clinical diagnosis of AS underwent right and left heart catheterization and a novel dynamic coronary angiographic technique. Twenty AS patients without coronary artery disease (CAD) were enrolled. All patients were divided into either: group A for severe AS or group B for mild to moderate AS. The control group consisted of Five patients with normal left ventricular function without CAD nor AS (group C). The flow data included the coronary transit time duration, the presence of retrograde flow at the proximal coronary segment, and the persistence of contrast spill-out from the coronary ostium.

Results There was prolonged arterial phase and retrograde flow in the proximal coronary segment, including persistent spilling of contrast into the coronary sinus ($p<0.01$ when compared with groups B and C) in 20 patients with severe AS (group A). In 24 patients in the mild to moderate AS group (group C), there was only a moderately prolonged arterial phase without retrograde flow nor spilling of contrast from the ostium ($p=0.99$ when compared with control group C).

Conclusions In patients with AS, significantly prolonged arterial coronary transit time, reversed coronary flow, and retrograde ejection of contrast into the coronary sinus correlated statistically with the severity of AS. In patients with mild to moderate AS, with only moderate prolongation of the arterial phase without reversed coronary flow nor retrograde ejection of contrast into the coronary sinus.

KEYWORDS Aortic stenosis, chest pain, patent coronary artery, syncope, prolonged arterial phase, reversed flow, sudden cardiac death

TTU JOURNAL OF BIOMEDICAL SCIENCES, VOLUME 02, 2023

24

FIGURE 1. Original version of the sample 1.

diagnosis of AS underwent right and left heart catheterization and a novel dynamic coronary angiographic technique. Twenty AS patients without coronary artery disease (CAD) were enrolled. All patients were divided into either: group A for severe AS or group B for mild to moderate AS. The control group consisted of Five patients with normal left ventricular function without CAD or AS (group C). The flow data included the coronary transit time duration, the presence of retrograde flow at the proximal coronary segment, and the persistence of contrast spill-out from the coronary ostium.

Results. There was prolonged arterial phase and retrograde flow in the proximal coronary segment, including persistent spilling of contrast into the coronary sinus ($p<0.01$ when compared with groups B and C) in 20 patients with severe AS (group A). In 24 patients in the mild to moderate AS group (group C), there was only a moderately prolonged arterial phase without retrograde flow nor spilling of contrast from the ostium ($p=0.99$ when compared with control group C).

Conclusions. In patients with AS, significantly prolonged arterial coronary transit time reversed coronary flow, and retrograde ejection of contrast into the coronary sinus correlated statistically with the severity of AS. In patients with mild to moderate AS, with only moderate prolongation of the arterial phase without reversed coronary flow nor retrograde ejection of contrast into the coronary sinus.

The following version has been edited with the assistance of ChatGPT (Table 1), (Figure 2) and then corrected by an editor (Table 2):

Background: Aortic stenosis (AS) is a medical condition that can cause symptoms such as chest pain, shortness of breath, and syncope in patients with no lesion in coronary arteries. The pathophysiology of these symptoms is not well understood when there is no coronary artery stenosis. Therefore, we conducted a study to investigate the mechanism of chest pain, shortness of breath, and syncope in AS patients without coronary artery stenosis, based on coronary flow patterns or abnormalities.

Methods: We screened 132 patients who visited the emergency room with chest pain, shortness of breath, or syncope

TABLE 1. Common assistance from ChatGPT and syntaxes.

Assistance	Syntaxes
Grammar and spelling checks	<i>Please check grammar and spelling of the following: "..."</i>
Punctuation and capitalization checks	<i>Please check Punctuation and capitalization of the following: "..."</i>
Style and tone suggestions	<i>Please give me some suggestions to rewrite the following with a formal, objective and precise tone, and with a clear and concise style: "..."</i>
Sentence restructuring and rephrasing	<i>Please restructure the following to make it more understandable: "..."</i> <i>Please paraphrase this following sentence: "..."</i>
Contextual feedback	<i>Please give me contextual feedbacks for the following: "..."</i>
Consistency checks	<i>Please check consistency of the following and make suggestions if possible: "..."</i>
Fact-checking	<i>Please fact-check the following: "..."</i>
Citation and reference check	<i>Please check and correct the following references in the ACM (or ACS or IEEE or etc.) format: "..."</i>
Plagiarism detection	<i>Please check plagiarism in the following: "..."</i>
Language translation	<i>Please translate the following to English: "..."</i>

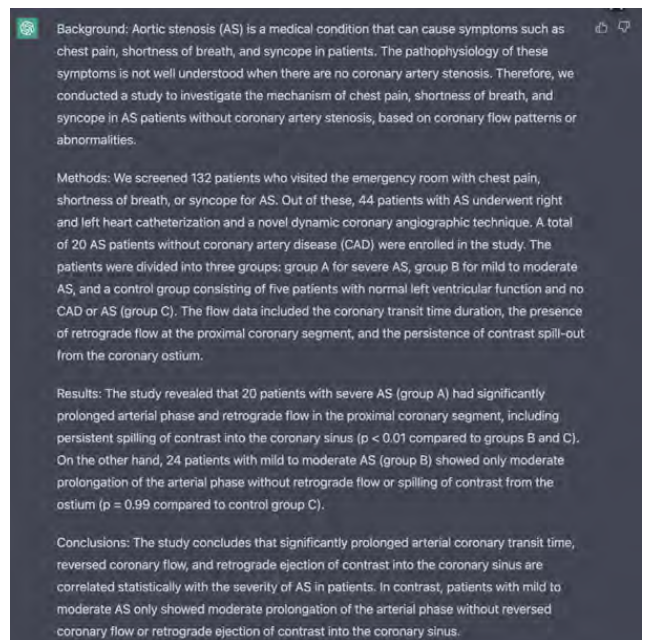


FIGURE 2. Response of ChatGPT after several syntaxes for sample 1.

TABLE 2. Comparison between ChatGPT's version versus the final version by combination of ChatGPT and an editor in the sample 1.

ChatGPT's version	Corrected version	Reason
<i>Aortic stenosis (AS) is a medical condition that can cause symptoms such as chest pain, shortness of breath, and syncope in patients.</i>	<i>Aortic stenosis (AS) is a medical condition that can cause symptoms such as chest pain, shortness of breath, and syncope in patients with no lesion in coronary arteries.</i>	ChatGPT's version may not show the author's intention. (Contextual error)
	Other minimal changes in formatting were made.	

for AS. Out of these, 44 patients with AS underwent right and left heart catheterization and a novel dynamic coronary angiographic technique. A total of 20 AS patients without coronary artery disease (CAD) were enrolled in the study. The patients were divided into three groups: group A for severe AS, Group B for mild to moderate AS, and a control group consisting of five patients with normal left ventricular function and no CAD or AS (Group C). The flow data included the coronary transit time duration, the presence of retrograde flow at the proximal coronary segment, and the persistence of contrast spill-out from the coronary ostium.

Results: The study revealed that 20 patients with severe AS (group A) had significantly prolonged arterial phase and retrograde flow in the proximal coronary segment, including persistent spilling of contrast into the coronary sinus ($p < 0.01$ compared to groups B and C). On the other hand, 24 patients with mild to moderate AS (group B) showed only moderate prolongation of the arterial phase without retrograde flow or spilling of contrast from the ostium ($p = 0.99$ compared to control group C).

Conclusions: The study concludes that significantly prolonged arterial coronary transit time, reversed coronary flow, and retrograde ejection of contrast into the coronary sinus are correlated statistically with the severity of AS in patients. In contrast, patients with mild to moderate AS only showed moderate prolongation of the arterial phase without reversed coronary flow or retrograde ejection of contrast into the coronary sinus.

Sample 2:

This is the original version of the method section from the article titled "Questions on the Genesis and Growth of Coronary Lesions and their Answers Based on Fluid Mechanics Engineering: A New Dynamic Angiography Analysis" (Figure 3) [17].

METHOD

NEW Technique of Filming and Reviewing Coronary Angiography

According to current practice, the CAG technique requires the operators to fill the coronary lumen with contrast to detect a defect or indentation of the contrasting shadow of

INTRODUCTION

Currently, explanations for the genesis and growth of atherosclerotic coronary lesions remain elusive and unconvincing. In the quest for new strategies and methodologies in coronary artery research, the present team of investigators has turned to the field of fluid mechanics, examining the patterns of damage seen in industrial pipes and pumps. By applying the same fluid mechanics theory and practice to the cardiovascular system, our new hypothesis was built on the concept that flow abnormalities damage the intima and prompt the formation, growth, and/or rupture of atherosclerotic plaques [1]-[3]. When a patient received multiple coronary angiograms (CAGs) over the course of years or underwent staged percutaneous coronary interventions (PCI), the approach was to search for the transformation from one type of flow to another and to correlate these flow dynamics with the appearance, severity, growth, regression, or rupture of lesions. To support the detailed investigation of coronary or peripheral flow, the current technique of angiography was redesigned and reprogrammed so it could provide precise details of flow movements, such as changes in direction, intensity, and speed [4], [5].

This article serves as a roadmap for researchers and readers to understand the rationale behind classifying lesions by flow type, and it also aims to decipher the similarities and differences observed when comparing flows and lesions in coronary arteries versus those in pipes. One important ongoing project employs fluid mechanics to explain the beneficial mechanisms of control-fracturing coronary plaques with plain balloon angioplasty (POBA), shaving the calcified superficial layers with rotational atherectomy, weakening the calcified wall with intravascular lithotripsy, or scaffolding the arterial lumen with a bioabsorbable vascular scaffold (BVS) or the struts of a stent. In this article, an overview of questions and answers generated from completed studies and preliminary results of ongoing research will be presented. The angiographic coronary images of recirculation flow, vortex formation, collision, hammer water shock, and cavitation serve will be showcased in details and their videos in slow motion are uploaded on the addendum for further in-depth review.

METHODS

NEW Technique of Filming and Reviewing Coronary Angiography

According to current practice, the CAG technique requires the operators to fill the coronary lumen with contrast to detect a defect or indentation of the contrasting shadow of the lumen (i.e., "luminogram") and subsequently classify such a defect as a lesion or stenosis. This technology can only show the static image of a narrowing of the arterial channel without explaining the mechanism of the disease or predicting its progression or regression. Therefore, to examine the dynamics of the blood flow in more details, the current recording and reviewing techniques of CAGs were redesigned and reprogrammed by the present team of

TABLE 1. Questions to be Asked When Seeing a Coronary Lesion Based on Fluid Mechanics Engineering Perspective

1. What is its severity?
2. Where is its location? At the ostium? At the proximal, middle, or distal segment?
3. How is it related to a nearby bifurcation or side branch? Proximal to the bifurcation? Distal to the bifurcation? At the ostium of the distal main vessel? At the ostium of the side branch?
4. Why does it happen here, instead of at a different location of the coronary system? All segments of the 3 coronary arteries are under the effects of the same risk factors if there are: hypertension, diabetes, smoking, high cholesterol level, aging, etc. What is the fluid mechanic mechanism?
5. Was the mechanism of formation of the lesion similar to the mechanism causing damage inside a pipe or pump? Could it be a collision, vortex formation, turbulence, water hammer shock, cavitation or recirculation flow?
6. How did the lesion grow? Did it grow fast, or did it grow slow? After 40 or 50 years? Or after a few months?
7. What did the distal flow change as the lesion became more severe? How did the new flow affect the formation and growth of new lesions downstream?
8. What were the effects on coronary flow after the lumen is enlarged and scaffolded by a stent?

investigators. This new technique focused on the flow itself, identifying its patterns and analyzing its abnormalities based on the same methodology used by fluid mechanic engineers in domestic and industrial pipes [5]. A detailed description of the method was previously published, and a short summary is presented below [5].

First, the contrast was injected until the index coronary artery was completely opacified. When some contrast (colored black) was seen ejected back from the coronary ostium into the aorta, the manual injection was halted. At this moment, the blood (visualized as white) moved in quickly to displace the contrast. The shape, movements, directions, and interactions of the blood flow in white could be clearly observed upon the black contrast background. The CAG was recorded from the beginning of injection until all the contrast disappeared from the distal arterial vasculature (i.e., arterial phase), and ended after the contrast was no longer visible in the coronary veins (i.e., venous phase).

During the recording, the camera was positioned at an angle that could record the index artery and vein in their full length, with all the images completely within the limits of the frame, at 15 images per second (sec), or an interval of 67 milliseconds (msec) between images [5]. The angiograms were saved and stored in the EPIC Electronic Health Record (EHR) System (Epic Systems Corporation, Madison, WI).

QUESTIONS on the Genesis, Growth, Rupture, and Demise of Coronary Lesions

Once there is a lesion of every degree of severity (mild, moderate to severe), there many questions to be asked about its birth, growth, rupture, or demise (becoming a chronic total occlusion) are listed in Table 1. Different types of lesions and questions are included in Figure 1.

FIGURE 3. The original version of the sample 2.

the lumen (i.e., "luminogram") and subsequently classify such a defect as a lesion or stenosis. This technology can only show the static image of a narrowing of the arterial channel without explaining the mechanism of the disease or predicting its progression or regression. Therefore, to examine the dynamics of the blood flow in more detail, the current recording and reviewing techniques of CAGs were redesigned and reprogrammed by the present team of investigators. This new technique focused on the flow itself, identifying its patterns and analyzing its abnormalities based on the same methodology used by fluid mechanic engineers in domestic and industrial pipes [5]. A detailed description of the method was previously published, and a short summary is presented below [5].

First, the contrast was injected until the index coronary artery was completely opacified. When some contrast (colored black) was seen ejected back from the coronary ostium into the aorta, the manual injection was halted. At this moment, the blood (visualized as white) moved in quickly to displace the contrast. The shape, movements, directions, and interactions of the blood flow in white could be clearly observed in the black contrast background. The CAG was recorded from the beginning of injection until all the contrast disappeared from the distal arterial vasculature (i.e., arterial

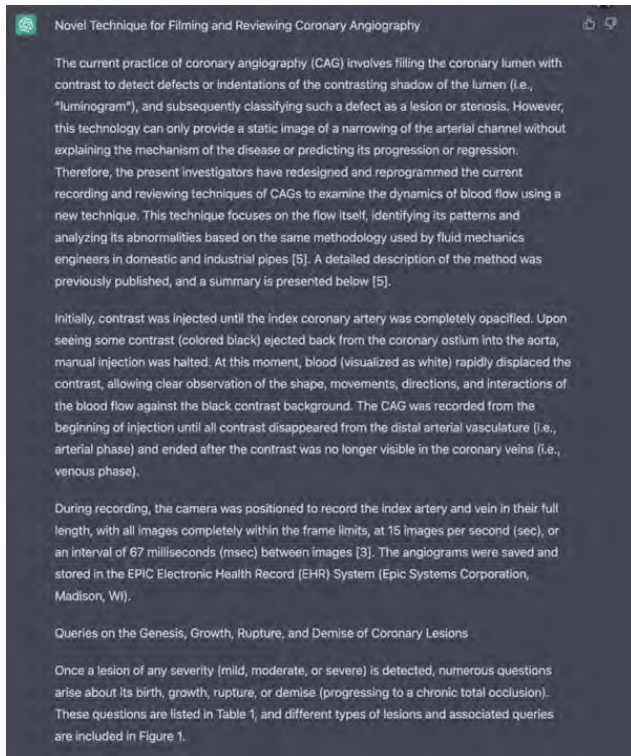


FIGURE 4. Response of ChatGPT after several syntaxes for sample 2.

phase), and ended after the contrast was no longer visible in the coronary veins (i.e., venous phase).

During the recording, the camera was positioned at an angle that could record the index artery and vein at their full length, with all the images completely within the limits of the frame, at 15 images per second (sec), or an interval of 67 milliseconds (msec) between images [3]. The angiograms were saved and stored in the EPIC Electronic Health Record (EHR) System (Epic Systems Corporation, Madison, WI).

QUESTIONS on the Genesis, Growth, Rupture, and Demise of Coronary Lesions

Once there is a lesion of every degree of severity (mild, moderate to severe), there are many questions to be asked about its birth, growth, rupture, or demise (becoming a chronic total occlusion) listed in Table 1. Different types of lesions and questions are included in Figure 1.

This is the version that has been edited with the assistance of ChatGPT (Table 1), (Figure 4) and then corrected by an editor (Table 3):

Methods

Novel Technique for Filming and Reviewing Coronary Angiography

The current practice of coronary angiography (CAG) involves filling the coronary lumen with contrast to detect defects or indentations of the contrasting shadow of the lumen (i.e., “luminogram”), and subsequently classifying such a defect as a lesion or stenosis. However, this technology can only provide a static image of a narrowing of the arterial channel without explaining the mechanism of the

TABLE 3. Comparison between ChatGPT’s version versus the final version by the combination of ChatGPT and an editor in sample 2.

ChatGPT’s version	Corrected version	Reason
... the present investigators have redesigned and reprogrammed the current recording and reviewing techniques of CAGs...	... the present team of investigators has redesigned and reprogrammed the current recording and reviewing techniques of CAGs...	To avoid the misunderstanding that those investigators worked independently.
... Queries on the Genesis, Growth, Rupture, and Demise of Coronary Lesions...	... QUESTIONS on the Genesis, Growth, Rupture, and Demise of Coronary Lesions...	To preserve the author’s intention.
... the camera was positioned to record the index artery and vein in their full length, with all images completely within the frame limit...	... the camera was positioned to record the index artery and vein at their full length, with all images completely within the frame limit...	“at” will be more appropriate than “in” in this circumstance.
	Other minimal changes in formatting were made.	

disease or predicting its progression or regression. Therefore, the present team of investigators has redesigned and reprogrammed the current recording and reviewing techniques of CAGs to examine the dynamics of blood flow using a new technique. This new technique focuses on the flow itself, identifying its patterns and analyzing its abnormalities based on the same methodology used by fluid mechanics engineers in domestic and industrial pipes [5]. A detailed description of the method was previously published, and a summary is presented below [5].

Initially, contrast was injected until the index coronary artery was completely opacified. Upon seeing some contrast (colored black) ejected back from the coronary ostium into the aorta, the manual injection was halted. At this moment, the blood (visualized as white) rapidly displaced the contrast, allowing clear observation of the shape, movements, directions, and interactions of the blood flow against the black contrast background. The CAG was recorded from the beginning of injection until all contrast disappeared from the distal arterial vasculature (i.e., arterial phase) and ended after the contrast was no longer visible in the coronary veins (i.e., venous phase).

During recording, the camera was positioned to record the index artery and vein at their full length, with all images completely within the frame limits, at 15 images per second (sec), or an interval of 67 milliseconds (msec) between images [3]. The angiograms were saved and stored in the EPIC Electronic Health Record (EHR) System (Epic Systems Corporation, Madison, WI).

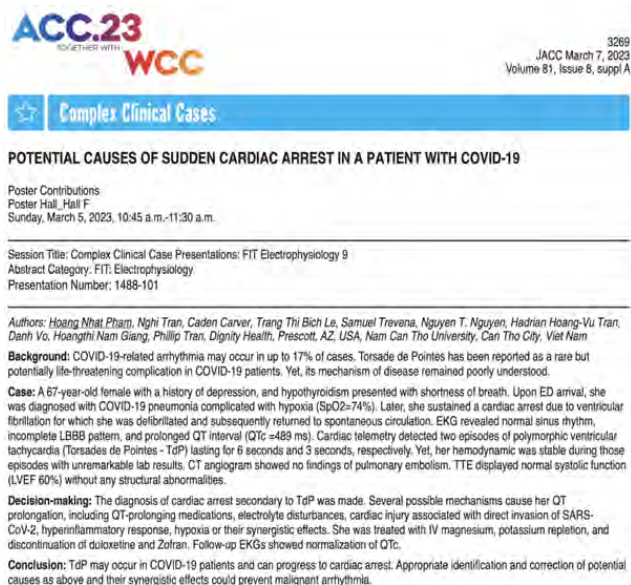


FIGURE 5. The original version of the sample 3.

QUESTIONS on the Genesis, Growth, Rupture, and Demise of Coronary Lesions

Once a lesion of any severity (mild, moderate, or severe) is detected, many questions arise about its birth, growth, rupture, or demise (progressing to a chronic total occlusion). These questions are listed in Table 1, and different types of lesions and associated queries are included in Figure 1.

Sample 3:

This is the original version of a case report titled “Potential Causes of Sudden Cardiac Arrest in A Patient with Covid-19” (Figure 5) [18].

Background: COVID-19-related arrhythmia may occur in up to 17% of cases. Torsade de Pointes has been reported as a rare but potentially life-threatening complication in COVID-19 patients. Yet, its mechanism of disease remained poorly understood.

Case: A 67-year-old female with a history of depression, and hypothyroidism presented with shortness of breath. Upon ED arrival, she was diagnosed with COVID-19 pneumonia complicated with hypoxia (SpO₂=74%). Later, she sustained a cardiac arrest due to ventricular fibrillation for which she was defibrillated and subsequently returned to spontaneous circulation. EKG revealed normal sinus rhythm, incomplete LBBB pattern, and prolonged QT interval (QTc =489 ms). Cardiac telemetry detected two episodes of polymorphic ventricular tachycardia (Torsades de Pointes - TdP) lasting for 6 seconds and 3 seconds, respectively. Yet, her hemodynamic was stable during those episodes with unremarkable lab results. CT angiogram showed no findings of pulmonary embolism. TTE displayed normal systolic function (LVEF 60%) without any structural abnormalities.

Decision-making: The diagnosis of cardiac arrest secondary to TdP was made. Several possible mechanisms cause

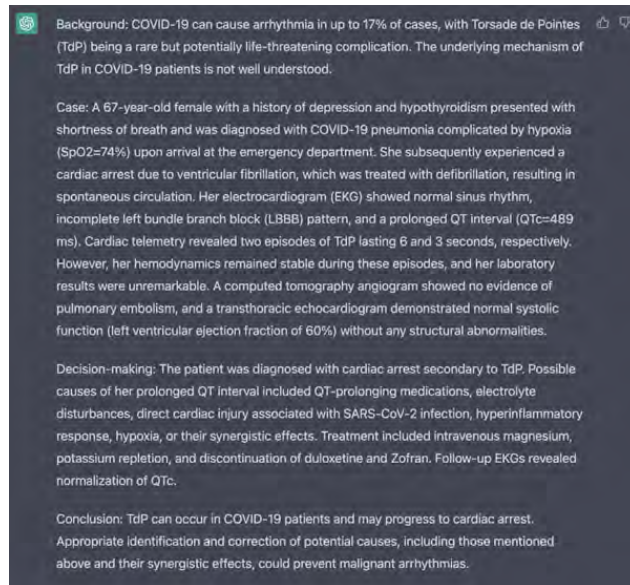


FIGURE 6. Response of ChatGPT after several syntaxes for sample 3.

TABLE 4. Comparison between ChatGPT’s version versus the final version by the combination of ChatGPT and an editor in sample 3.

ChatGPT’s version	Corrected version	Reason
	Other minimal changes in formatting were made.	

her QT prolongation, including QT-prolonging medications, electrolyte disturbances, cardiac injury associated with direct invasion of SARS-CoV-2, hyperinflammatory response, hypoxia or their synergistic effects. She was treated with IV magnesium, potassium repletion, and discontinuation of duloxetine and Zofran. Follow-up EKGs showed normalization of QTc.

Conclusion: TdP may occur in COVID-19 patients and can progress to cardiac arrest. Appropriate identification and correction of potential causes as above and their synergistic effects could prevent malignant arrhythmia.

This is the version that has been edited with the assistance of ChatGPT (Table 1), (Figure 6) and then corrected by an editor (Table 4):

Background: COVID-19 can cause arrhythmia in up to 17% of cases, with Torsade de Pointes (TdP) being a rare but potentially life-threatening complication. The underlying mechanism of TdP in COVID-19 patients is not well understood.

Case: A 67-year-old female with a history of depression and hypothyroidism presented with shortness of breath and was diagnosed with COVID-19 pneumonia complicated by hypoxia (SpO₂=74%) upon arrival at the emergency department. She subsequently experienced a cardiac arrest due to ventricular fibrillation, which was treated with defibrillation, resulting in spontaneous circulation. Her electrocardiogram (EKG) showed normal sinus rhythm, incomplete left bundle

On follow-up on April 2021, patient was asymptomatic. His physical examination was unremarkable, and EKG demonstrated normal sinus rhythm.

3. DISCUSSION

Since December 2019, the world has been suffering from devastating pandemic caused by a novel virus SARS-CoV-2. By January 2021, the number of people who were infected with COVID-19 have surpassed 80 million worldwide, leading to over 1.7 million deaths. In addition to respiratory manifestations, various cardiac complications have been increasingly reported in patients with COVID-19 infection, including but not limited to acute coronary syndrome, heart failure, left ventricular dysfunction, and myocarditis.^[2] Arrhythmias and correlated symptoms have also been reported, with sinus tachycardia being the most common finding. However, bradycardia is relatively uncommon (0.9% - 30.8%).^[2-7] The time of onset of bradycardia varies from 4 days to 3 weeks.^[2-7] During bradycardic episodes, patients usually had normal cardiac biomarkers, normal EKG, and echocardiogram.^[8-12] Fortunately, most of symptoms did not persist after patients recovered from COVID-19 infection.^[8]

3.1 Mechanism

The underlying etiology of bradycardia in COVID-19 patients seems to be multifactorial.^[2,13] The proposed mechanisms include respiratory dysfunction resulting in hypoxia, systemic and local inflammatory responses releasing pro-inflammatory cytokines, myocardial injury, and side effects of drugs. The normal cardiac biomarkers values commonly found in COVID-19 patients experiencing bradycardia favor the hypothesis that the virus causes bradycardia through other pathways rather than direct cardiac cell destruction.^[6,8,10,12,14] The arrhythmogenicity of SARS-CoV-2 remains controversial.

This new coronavirus has been well-documented to invade cells using angiotensin-converting enzyme 2 (ACE-2) receptor

Published by Sciendo Press

tor, which is widely expressed in the cardiovascular system including cardiomyocytes, endothelial cells, macrophages, and other interstitial cells. The presence of ACE-2 in SA node reported in recent animal studies and the conduction disturbances following altered ACE-2 expression suggested possible direct inhibitory effect of SARS-CoV-2 on SA node and conduction system.^[6,8]

Another hypothesis suggested that the coronavirus may cause dysfunction of the cardiorespiratory center along with autonomic nervous system. Several cases have been reported to be able to spread from the respiratory airways to the medullary cardiorespiratory center through synaptic transmission. This hypothesis may take responsibility for the simultaneous presence of both respiratory and cardiac collapse in numerous COVID-19 infected patients.^[15] In addition, altered ion channel functions secondary to interstitial edema, abnormal intercellular coupling and another features of local inflammatory process could also be involved, as seen in other arrhythmias in viral infection.^[16]

On the other hand, the elevation of inflammatory markers may play a major role in eliciting inflammatory response in the etiology of bradycardia. The pro-inflammatory cytokines, most prominently IL-6, significantly contribute to the pathogenesis of relative bradycardia. The excessive release of cytokines is suggested as a sign of worsening inflammatory reactions as well as a prediction of upcoming cytokine storm.^[7] Additionally, the currently used medications for patients with COVID-19 infections may also contribute to the bradycardia in such patients. Anti-infective medications (azithromycin, chloroquine, lopinavir/ritonavir/remdesivir) or supportive treatment (propofol) potentially cause arrhythmia and bradycardia.^[2,7,9,13]

3.2 Relative bradycardia

Relative bradycardia describes the phenomenon where the heart rate does not increase appropriately with an increase

19

TABLE 5. Comparison between ChatGPT's version versus the final version by the combination of ChatGPT and an editor in sample 4.

ChatGPT's version	Corrected version	Reason
	Other minimal changes in formatting were made.	

proinflammatory cytokines, myocardial injury, and side effects of drugs. The normal cardiac biomarkers values commonly found in COVID-19 patients experiencing bradycardia favor the hypothesis that the virus causes bradycardia through other pathways rather than direct cardiac cell destruction [6], [8], [10], [12], [14]. The arrhythmogenicity of SARS-CoV-2 remains controversial.

This new coronavirus has been well-documented to invade cells using angiotensin-converting enzyme 2 (ACE-2) receptor, which is widely expressed in the cardiovascular system including cardiomyocytes, endothelial cells, macrophages, and other interstitial cells. The presence of ACE-2 in SA node reported in recent animal studies and the conduction disturbances following altered ACE-2 expression suggested a possible direct inhibitory effect of SARS-CoV-2 on SA node and conduction system [6], [8].

Another hypothesis suggested that the coronavirus may cause dysfunction of the cardiorespiratory center along with autonomic nervous system. Several cases have been reported to be able to spread from the respiratory airways to the medullary cardiorespiratory center through synaptic transmission. This hypothesis may take responsibility for the simultaneous presence of both respiratory and cardiac collapse in numerous COVID-19-infected patients [15]. In addition, altered ion channel functions secondary to interstitial edema, abnormal intercellular coupling, and other features of the local inflammatory process could also be involved, as seen in other arrhythmias in viral infection [16].

On the other hand, the elevation of inflammatory markers may play a major role in eliciting inflammatory response in the etiology of bradycardia. The pro-inflammatory cytokines, most prominently IL-6, significantly contribute to the pathogenesis of relative bradycardia. The excessive release of cytokines is suggested as a sign of worsening inflammatory reactions as well as a prediction of an upcoming cytokine storm [7]. Additionally, the currently used medications for patients with COVID-19 infections may also contribute to the bradycardia in such patients. Anti-infective medications (azithromycin, chloroquine, lopinavir/ritonavir/remdesivir) or supportive treatment (propofol) potentially cause arrhythmia and bradycardia [2], [7], [9], [13].

This is the version that has been edited with the assistance of ChatGPT (Table 1), (Figure 8) and then corrected by an editor (Table 5):

Mechanism

The etiology of bradycardia in COVID-19 patients is multifactorial [2], [13], involving respiratory dysfunction resulting in hypoxia, systemic and local inflammatory responses

FIGURE 7. The original version of the sample 4.

branch block (LBBB) pattern, and a prolonged QT interval (QTc=489 ms). Cardiac telemetry revealed two episodes of TdP lasting 6 and 3 seconds, respectively. However, her hemodynamics remained stable during these episodes, and her laboratory results were unremarkable. A computed tomography angiogram showed no evidence of pulmonary embolism, and a transthoracic echocardiogram demonstrated normal systolic function (left ventricular ejection fraction of 60%) without any structural abnormalities.

Decision-making: The patient was diagnosed with cardiac arrest secondary to TdP. Possible causes of her prolonged QT interval included QT-prolonging medications, electrolyte disturbances, direct cardiac injury associated with SARS-CoV-2 infection, hyperinflammatory response, hypoxia, or their synergistic effects. Treatment included intravenous magnesium, potassium repletion, and discontinuation of duloxetine and Zofran. Follow-up EKGs revealed normalization of QTc.

Conclusion: TdP can occur in COVID-19 patients and may progress to cardiac arrest. Appropriate identification and correction of potential causes, including those mentioned above and their synergistic effects, could prevent malignant arrhythmias.

Sample 4:

This is the original version of the mechanism section from the article titled "Significant bradycardia in patient with COVID-19 sepsis: Full management review" (Figure 7) [19].

Mechanism

The underlying etiology of bradycardia in COVID-19 patients seems to be multifactorial [2], [13]. The proposed mechanisms include respiratory dysfunction resulting in hypoxia, systemic and local inflammatory responses releasing

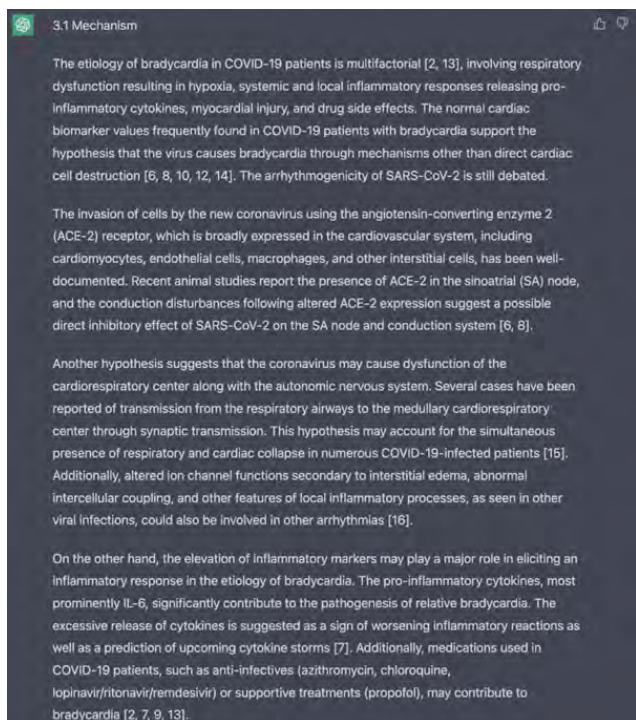


FIGURE 8. Response of ChatGPT after several syntaxes for sample 4.

releasing pro-inflammatory cytokines, myocardial injury, and drug side effects. The normal cardiac biomarker values frequently found in COVID-19 patients with bradycardia support the hypothesis that the virus causes bradycardia through mechanisms other than direct cardiac cell destruction [6], [8], [10], [12], [14]. The arrhythmogenicity of SARS-CoV-2 is still debated.

The invasion of cells by the new coronavirus using the angiotensin-converting enzyme 2 (ACE-2) receptor, which is broadly expressed in the cardiovascular system, including cardiomyocytes, endothelial cells, macrophages, and other interstitial cells, has been well-documented. Recent animal studies report the presence of ACE-2 in the sinoatrial (SA) node, and the conduction disturbances following altered ACE-2 expression suggest a possible direct inhibitory effect of SARS-CoV-2 on the SA node and conduction system [6], [8].

Another hypothesis suggests that the coronavirus may cause dysfunction of the cardiorespiratory center along with the autonomic nervous system. Several cases have been reported of transmission from the respiratory airways to the medullary cardiorespiratory center through synaptic transmission. This hypothesis may account for the simultaneous presence of respiratory and cardiac collapse in numerous COVID-19-infected patients [15]. Additionally, altered ion channel functions secondary to interstitial edema, abnormal intercellular coupling, and other features of local inflammatory processes, as seen in other viral infections, could also be involved in other arrhythmias [16].

On the other hand, the elevation of inflammatory markers

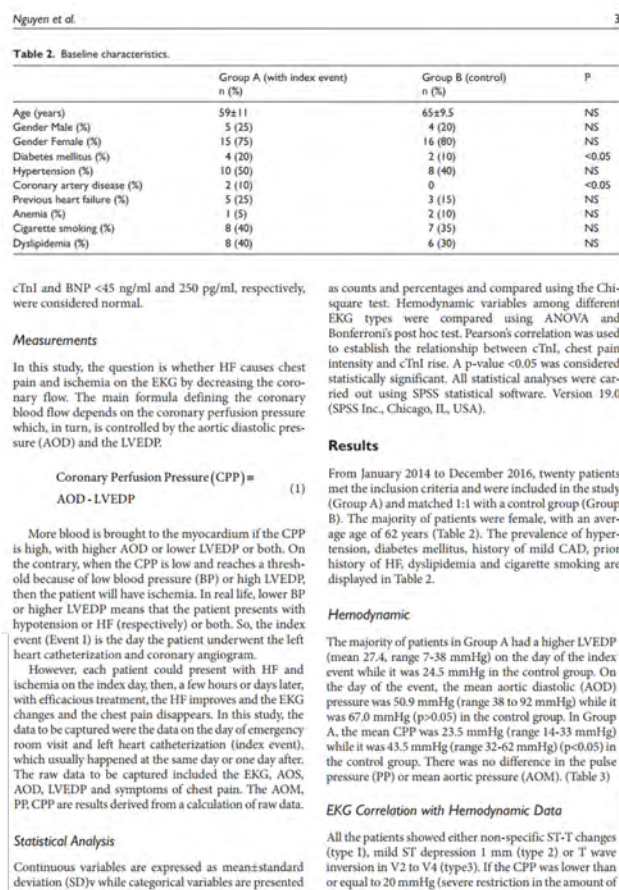


FIGURE 9. The original version of the sample 5 part 1.

may play a major role in eliciting an inflammatory response in the etiology of bradycardia. The pro-inflammatory cytokines, most prominently IL-6, significantly contribute to the pathogenesis of relative bradycardia. The excessive release of cytokines is suggested as a sign of worsening inflammatory reactions as well as a prediction of upcoming cytokine storms [7]. Additionally, medications used in COVID-19 patients, such as anti-infectives (azithromycin, chloroquine, lopinavir/ritonavir/remdesivir) or supportive treatments (propofol), may contribute to bradycardia [2], [7], [9], [13].

Sample 5:

This is the original version of the result section from the article titled "Left Ventricular Dysfunction Causing Ischemia in Patients with Patent Coronary Arteries" (Figure 9, 10) [20].

Results

From January 2014 to December 2016, twenty patients met the inclusion criteria and were included in the study (Group A) and matched 1:1 with a control group (Group B). The majority of patients were female, with an average age of 62 years (Table 2). The prevalence of hypertension, diabetes mellitus, history of mild CAD, prior history of HF,

Table 3. Hemodynamic data by groups. All variables are in mmHg.

	Group A	Group B (control)	P
Aortic diastolic pressure	50.9±12.5	67.0±7.80	>0.05
Left ventricular end diastolic pressure	27.4±14.2	24.5±13.2	NS
Aortic mean pressure	80±12.4	90±13.5	NS
Pulse pressure	40±7.8	45±2.3	NS
Coronary perfusion pressure	23.5±2.2	43.5±3.2	<0.005

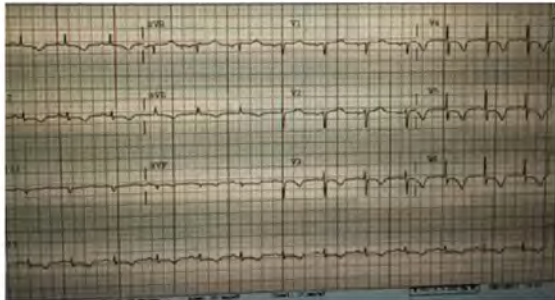

Figure 1. Type 3 EKG changes with diffuse deep T wave inversion.

blood perfusing the myocardium), the EKG changes showed deep T wave inversion 80% of the time (type 3) (Figure 1). If the CPP was between 20-30 mmHg, then the EKG changes were more of a mild ST depression (type 2) (Figure 2). If the CPP was above 30 mmHg (low normal coronary perfusion pressure), the EKG changes were normal or only of type 1 with non-specific ST-T changes (Figure 3).

The one exception was when the heart rate was above 100 beats per minute (BPM). In this situation, even though the CPP was between 20 to 30 mmHg, the patient still developed symptoms of chest pain and deep T wave inversion (more often of type 3 than type 1); it did not reach statistical significance.

A significant Pearson's correlation between the heart rate and the cTnI level was observed ($r=0.215, p=0.001$). Similarly, a correlation was identified between chest pain intensity and cTnI rise ($r=0.196, p=0.002$).

Symptom Changes with EKG

Almost all patients complained of some vague chest discomfort or atypical chest pain associated with the above

EKG changes. When the LV dysfunction or the AOD improved with treatment (CPP became higher), the symptom of chest pain disappeared with the ST-T segment returning to baseline within a few days or weeks (no more deep T wave inversion and the T waves became upright) (Figure 4, Table 4). In 18 out of 20 patients (90%), the ischemic EKG changes returned to normal after appropriate off-loading.

Hospitalization courses

There was no difference in the use of medications before and after the index event (aspirin, beta blockers, angiotensin-converting enzyme inhibitors, statin), except for diuretics. The patients in Group A had more re-admissions in the next 6 months to one year.

Discussion

The goal of the study was to clarify the relationship between LVEDP and AOD or both with the appearance of EKG changes and chest pain. This study had three main findings. The first finding showed that, in

TABLE 6. Comparison between ChatGPT's version versus the final version by the combination of ChatGPT and an editor in sample 5.

ChatGPT's version	Corrected version	Reason
... The prevalence of hypertension, diabetes mellitus, history of mild CAD, history of HF, dyslipidemia, and cigarette smoking were recorded in Table 2...	... The prevalence of hypertension, diabetes mellitus, history of mild CAD, prior history of HF, dyslipidemia, and cigarette smoking was recorded in Table 2...	"Prevalence" is usually considered as an uncountable noun.
... There was no difference in the use of medications before and after the index event (aspirin, beta blockers, angiotensin-converting enzyme inhibitors, statin), except for diuretics.	... There was no difference in the use of medications before and after the index event (aspirin, beta blockers, angiotensin-converting enzyme inhibitors, statin), except for diuretics. However, patients in Group A were readmitted more frequently in the subsequent 6 months to one year.	The last sentence can be the important information that the author may want to include.
	Other minimal changes in formatting were made.	

The one exception was when the heart rate was above 100 beats per minute (BPM). In this situation, even though the CPP was between 20 to 30 mmHg, the patient still developed symptoms of chest pain and deep T wave inversion (more often of type 3 than type 1); it did not reach statistical significance.

A significant Pearson's correlation between the heart rate and the cTnI level was observed ($r=0.215, p=0.001$). Similarly, a correlation was identified between chest pain intensity and cTnI rise ($r=0.196, p=0.002$).

Symptom Changes with EKG

Almost all patients complained of some vague chest discomfort or atypical chest pain associated with the above EKG changes. When the LV dysfunction or the AOD improved with treatment (CPP became higher), the symptom of chest pain disappeared with the ST-T segment returning to baseline within a few days or weeks (no more deep T wave inversion, and the T waves became upright) (Figure 4, Table 4). In 18 out of 20 patients (90%), the ischemic EKG changes returned to normal after appropriate off-loading.

Hospitalization courses

There was no difference in the use of medications before and after the index event (aspirin, beta blockers, angiotensin-converting enzyme inhibitors, statin), except for diuretics. The patients in Group A had more readmissions in the next 6 months to one year.

This is the version that has been edited with the assistance of ChatGPT (Table 1), (Figure 11) and then corrected by an editor (Table 6):

Results:

FIGURE 10. The original version of the sample 5 part 2.

dyslipidemia and cigarette smoking are displayed in Table 2. **Hemodynamic**

The majority of patients in Group A had a higher LVEDP (mean 27.4, range 7-38 mmHg) on the day of the index event while it was 24.5 mmHg in the control group. On the day of the event, the mean aortic diastolic (AOD) pressure was 50.9 mmHg (range 38 to 92 mmHg) while it was 67.0 mmHg ($p>0.05$) in the control group. In Group A, the mean CPP was 23.5 mmHg (range 14-33 mmHg) while it was 43.5 mmHg (range 32-62 mmHg) ($p<0.05$) in the control group. There was no difference in the pulse pressure (PP) or mean aortic pressure (AOM). (Table 3)

EKG Correlation with Hemodynamic Data

All the patients showed either non-specific ST-T changes (type 1), mild ST depression 1 mm (type 2), or T wave inversion in V2 to V4 (type 3). If the CPP was lower than or equal to 20 mmHg (severe restriction in the amount of blood perfusing the myocardium), the EKG changes showed deep T wave inversion 80% of the time (type 3) (Figure 1). If the CPP was between 20-30 mmHg, then the EKG changes were more of a mild ST depression (type 2) (Figure 2). If the CPP was above 30 mmHg (low normal coronary perfusion pressure), the EKG changes were normal or only of type 1 with non-specific ST-T changes (Figure 3).

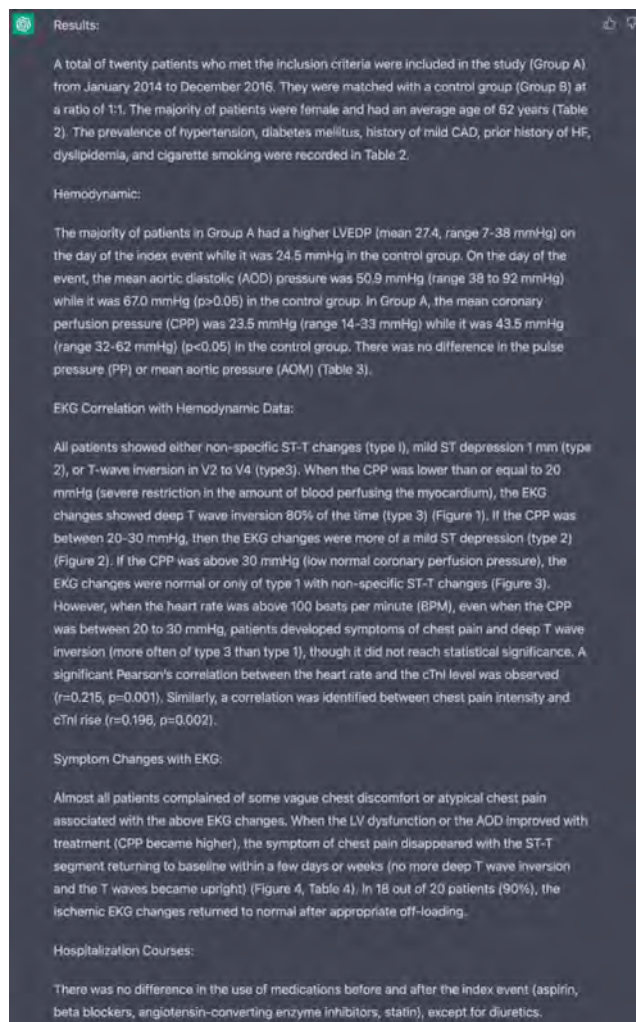


FIGURE 11. Response of ChatGPT after several syntaxes for sample 5.

A total of twenty patients who met the inclusion criteria were included in the study (Group A) from January 2014 to December 2016. They were matched with a control group (Group B) at a ratio of 1:1. The majority of patients were female and had an average age of 62 years (Table 2). The prevalence of hypertension, diabetes mellitus, history of mild CAD, prior history of HF, dyslipidemia, and cigarette smoking was recorded in Table 2.

Hemodynamic:

The majority of patients in Group A had a higher LVEDP (mean 27.4, range 7-38 mmHg) on the day of the index event while it was 24.5 mmHg in the control group. On the day of the event, the mean aortic diastolic (AOD) pressure was 50.9 mmHg (range 38 to 92 mmHg) while it was 67.0 mmHg ($p>0.05$) in the control group. In Group A, the mean coronary perfusion pressure (CPP) was 23.5 mmHg (range 14-33 mmHg) while it was 43.5 mmHg (range 32-62 mmHg) ($p<0.05$) in the control group. There was no difference in the pulse pressure (PP) or mean aortic pressure (AOM) (Table 3).

EKG Correlation with Hemodynamic Data:

All patients showed either non-specific ST-T changes (type 1), mild ST depression 1 mm (type 2), or T-wave inversion in V2 to V4 (type 3). When the CPP was lower than or equal to 20 mmHg (severe restriction in the amount of blood perfusing the myocardium), the EKG changes showed deep T wave inversion 80% of the time (type 3) (Figure 1). If the CPP was between 20-30 mmHg, then the EKG changes were more of a mild ST depression (type 2) (Figure 2). If the CPP was above 30 mmHg (low normal coronary perfusion pressure), the EKG changes were normal or only of type 1 with non-specific ST-T changes (Figure 3). However, when the heart rate was above 100 beats per minute (BPM), even when the CPP was between 20 to 30 mmHg, patients developed symptoms of chest pain and deep T wave inversion (more often of type 3 than type 1), though it did not reach statistical significance. A significant Pearson's correlation between the heart rate and the cTnI level was observed ($r=0.215$, $p=0.001$). Similarly, a correlation was identified between chest pain intensity and cTnI rise ($r=0.196$, $p=0.002$).

Symptom Changes with EKG:

Almost all patients complained of some vague chest discomfort or atypical chest pain associated with the above EKG changes. When the LV dysfunction or the AOD improved with treatment (CPP became higher), the symptom of chest pain disappeared with the ST-T segment returning to baseline within a few days or weeks (no more deep T wave inversion and the T waves became upright) (Figure 4, Table 4). In 18 out of 20 patients (90%), the ischemic EKG changes returned to normal after appropriate off-loading.

Hospitalization Courses:

There was no difference in the use of medications before and after the index event (aspirin, beta blockers, angiotensin-converting enzyme inhibitors, statin), except for diuretics. However, patients in Group A were readmitted more frequently in the subsequent 6 months to one year.

DISCUSSION

During the editing process, ChatGPT was able to identify several errors and inconsistencies in the manuscript, including grammatical errors, spelling mistakes, and punctuation errors. The model provided suggestions for improvement in sentence construction, word choice, and style, which were implemented by the authors. ChatGPT also identified several areas where the manuscript lacked coherence and suggested changes to improve the flow of the content.

After incorporating the changes suggested by ChatGPT, the manuscript was reviewed again by an editor. The editor noted that the manuscript had improved significantly in terms of clarity, coherence, and readability. The editor also noted that ChatGPT had identified several errors that were missed during the initial editing process and suggested changes that improved the overall quality of the manuscript. However, we observed that ChatGPT sometimes prioritizes brevity over accuracy, resulting in the omission of crucial phrases in complex sentences. This omission led to contextual errors in these sentences or the surrounding paragraph. This phenomenon was more pronounced in sentences that required a

high level of expertise to comprehend. ChatGPT also tends to expound upon ideas, resulting in lengthy sentences. This poses a challenge when creating abstracts for presentations at meetings, as there are strict word limits to adhere to. Consequently, ChatGPT may not be able to craft abstracts that are tailored to a well-informed audience of professionals, such as cardiologists, as it may include superfluous information, such as definitions of common conditions like aortic stenosis.

To evaluate the effectiveness of using ChatGPT for editing, we compared the edited manuscript with a control manuscript that was edited only by a professional editor. The control manuscript contained several errors and inconsistencies that were not identified by the editor, including grammatical errors, spelling mistakes, and punctuation errors. The control manuscript also lacked coherence and flow in several areas.

Overall, our results suggest that using ChatGPT as an editing tool can significantly improve the quality of a manuscript. The model was able to identify several errors and inconsistencies that were missed by the professional editor and provided suggestions for improvement in sentence construction, word choice, and style. The model also identified areas where the manuscript lacked coherence and provided suggestions to improve the flow of the content. Incorporating the changes suggested by ChatGPT led to a significant improvement in the overall quality of the manuscript, as evaluated by a professional editor.

CONCLUSION

In conclusion, the findings of this study suggest that ChatGPT can be a valuable tool in manuscript editing, providing authors with real-time feedback and suggestions for improving the quality and coherence of their written content. Our results demonstrate that ChatGPT was able to detect and correct grammatical, spelling, and punctuation errors with high accuracy and efficiency, and also provided valuable insights into the structure, organization, and argumentation of the content. Additionally, ChatGPT was able to provide consistent and unbiased feedback, regardless of personal preferences or biases, making it a reliable and valuable tool for authors.

However, while the use of ChatGPT in manuscript editing has shown promise, there are still some limitations and areas for further research. For example, our study focused on the technical aspects of editing, such as grammar and punctuation, and future research should investigate the potential of ChatGPT in detecting and correcting more complex issues, such as contextual and stylistic errors. In addition, there is a need to develop guidelines and standards for the use of ChatGPT in manuscript editing, as well as explore the ethical and social implications of using AI in the publishing industry.

Overall, ChatGPT has the potential to revolutionize the manuscript editing process, making it more efficient, accurate, and accessible for authors. By combining the expertise of human editors with the speed and efficiency of AI technology, we can improve the quality of written content and increase the chances of successful publication. We hope that

our study will contribute to the growing body of literature on AI-based manuscript editing and inspire further research in this field.

ADDENDUM: USING CHATGPT FOR EFFECTIVE MANUSCRIPT EDITING

Introduction

In this addendum, we will provide more detailed instructions on how to effectively use ChatGPT for editing manuscripts. We will cover various features available in ChatGPT, including grammar and spelling checks, punctuation and capitalization checks, style and tone suggestions, sentence restructuring and rephrasing, contextual feedback, consistency checks, fact-checking, citation and reference checks, plagiarism detection, language translation, and more. We will also explain how to use the regenerate response feature in ChatGPT to create different versions of the answers.

Syntaxes and Prefixes in ChatGPT

There are two primary methods to utilize the editing capabilities of ChatGPT. The initial method involves utilizing the provided syntaxes to communicate with the model in a structured manner. The syntaxes are purposefully designed to provide clear and concise instructions to the model, allowing users to request specific editing tasks. The second approach is to engage in an interactive chat with ChatGPT, using natural language to convey editing requirements. While this method may be less structured than using syntaxes, it can be beneficial for users who are unfamiliar with the available syntaxes or require clarification on how to utilize them. In order to provide a cohesive and concise demonstration of the instruction, syntaxes will be utilized in this instruction.

"!" - This prefix is used for most syntax commands in ChatGPT. Here are some examples:

!summarize: Summarizes a block of text.

!translate: Translates text to another language.

!synonyms: Provides synonyms for a given word.

!antonyms: Provides antonyms for a given word.

Examples and Tips

1. Grammar and Spelling Checks

Syntax: !check grammar "your text here"

Example: !check grammar "I am a writer."

Tip: Use this syntax to check your text for any grammatical or spelling errors. ChatGPT will highlight any issues and provide suggested corrections.

2. Punctuation and Capitalization Checks

Syntax: !check punctuation "your text here"

Example: !check punctuation "i am a writer"

Tip: Use this syntax to check for any errors related to punctuation or capitalization in your text. ChatGPT will highlight any issues and provide suggested corrections.

3. Style and Tone Suggestions

Syntax: !suggest style "your text here"

Example: !suggest style "This paragraph feels too formal."

Tip: Use this syntax to get suggestions from ChatGPT on how to improve the style and tone of your writing. ChatGPT

will provide suggestions on how to make your writing more engaging and readable.

4. Sentence Restructuring and Rephrasing

Syntax: !rephrase "your text here"

Example: !rephrase "The research study concluded that the results were significant."

Tip: Use this syntax to rephrase and restructure sentences to make them clearer and more concise. ChatGPT will provide suggestions for alternate phrasing and sentence structures.

5. Contextual Feedback

Syntax: !context "your text here"

Example: !context "It's raining cats and dogs."

Tip: Use this syntax to get feedback from ChatGPT on the context and meaning of your writing. ChatGPT will provide suggestions on how to make your writing more clear and meaningful.

6. Consistency Checks

Syntax: !check consistency "your text here"

Example: !check consistency "In the introduction, the author states that the study was conducted in 2021, but in the conclusion, they mention 2020."

Tip: Use this syntax to check for consistency errors in your writing. ChatGPT will identify any inconsistencies and provide suggestions on how to make your writing more consistent.

7. Fact-Checking

Syntax: !factcheck "your text here"

Example: !factcheck "The capital of Canada is Toronto."

Tip: Use this syntax to fact-check information in your writing. ChatGPT will verify the accuracy of the information and provide feedback if any inaccuracies are detected.

8. Citation and Reference Checks

Syntax: !check citation "your text here"

Example: !check citation "According to Johnson (2020), the study showed significant results."

Tip: Use this syntax to check the accuracy of citations and references in your writing. ChatGPT will verify the correctness of the citation and provide feedback if any errors are detected.

9. Plagiarism Detection

Syntax: !check plagiarism "your text here"

Example: !check plagiarism "This is a sentence from a published article."

Tip: Use this syntax to check your writing for any instances of plagiarism. ChatGPT will compare your text to online sources and identify any potential matches.

10. Language Translation

Syntax: !translate "text to be translated" to "language"

Example: !translate "Hello, how are you?" to "Spanish"

Tip: Use this syntax to translate your writing into another language. ChatGPT will provide a translation based on the specified language.

The "Regenerate Response" Feature

The "Regenerate Response" feature in ChatGPT is a powerful tool that can assist users in creating different variations

of the same response. This feature enables users to generate multiple responses to a single prompt by requesting the model to create a new response based on the original prompt. To make use of this feature effectively, users can simply input the original prompt and request ChatGPT to generate multiple responses. The model will then generate various responses based on the original prompt, each with its own distinct wording and structure. Users can choose one of these versions by reviewing each response and selecting the one that best suits their needs. Alternatively, they can combine elements of multiple responses to create a new and unique response.

To use the "Regenerate Response" feature effectively, here are some helpful tips:

- **Begin with a clear and specific prompt:** The more specific the prompt, the more focused the generated responses will be. This will assist users in finding the most relevant response more quickly.
- **Use the "Stop" command:** Users can signal to ChatGPT when to end the response generation by using the "Stop" command. For example, users can input "Stop after 5 responses" to generate five different responses.
- **Review and compare responses:** It is critical to carefully review each response and compare them to find the most suitable version for the user's needs. Factors such as clarity, tone, and relevance can be considered when selecting a response.
- **Combine responses:** Users can also combine elements of different responses to create a new, unique response. This can be useful when none of the generated responses fully meet their needs.

In conclusion, the "Regenerate Response" feature in ChatGPT can be a valuable tool for efficiently generating multiple versions of a response. By adhering to these tips, users can utilize this feature effectively to find the most appropriate response for their needs.

Conclusion:

These are some of the syntaxes that can be used in ChatGPT for various manuscript editing tasks. By using these syntaxes and tips, users can significantly improve the quality of their writing and ensure that their manuscripts are error-free and easy to read. However, it is important to keep in mind that ChatGPT is an AI language model and not a substitute for human editors or proofreaders. Therefore, it is always a good idea to have a professional editor review your work before submitting it for publication.

CONFLICTS OF INTEREST

None of the authors have conflicts of interest to declare.

REFERENCES

- [1] Garner BA, Garner BAGarner's modern English usage.
- [2] American-Medical-Association.AMA Manual of Style: A Guide for Authors and Editors. Oxford University Press, 2020. [Online]. Available: <https://doi.org/10.1093/jama/9780190246556.001.0001>

- [3] Bajwa SJS, Sawhney C“Preparing manuscript: Scientific writing for publication.” *Indian journal of anaesthesia*, Sep. 2016, 60:674–678, DOI: 10.4103/0019-5049.190625, PMID: 27729696.
- [4] Cho Hye-Min“Scientific Style and Format: The CSE Manual for Authors, Editors, and Publishers (8th edition),” *Sci Ed*, 2015, 2:44–45, DOI: 10.6087/kcse.38. [Online]. Available: <http://www.escienceediting.org/journal/view.php?number=41>
- [5] Huh S“Recent Issues in Medical Journal Publishing and Editing Policies: Adoption of Artificial Intelligence, Preprints, Open Peer Review, Model Text Recycling Policies, Best Practice in Scholarly Publishing 4th Version, and Country Names in Titles.” *Neurointervention*, Mar. 2023, 18:2–8, DOI: 10.5469/neuroint.2022.00493, PMID: 36720475.
- [6] Costa S“Medical Writing | Artificial intelligence and Digital Health | Embracing a new friendship: Artificial intelligence and medical writers.” [Online]. Available: <https://journal.emwa.org/artificial-intelligence-and-digital-health/embracing-a-new-friendship-artificial-intelligence-and-medical-writers/>
- [7] Razack HIA, Mathew ST, Saad FFA et al.“Artificial intelligence-assisted tools for redefining the communication landscape of the scholarly world,” *Science Editing*, 2021, 8:134–144, DOI: 10.6087/KCSE.244. [Online]. Available: <http://www.escienceediting.org/journal/view.php?doi=10.6087/kcse.244>
- [8] Soyer P“Medical writing and artificial intelligence,” *Diagnostic and Interventional Imaging*, 2019, 100:1–2, DOI: <https://doi.org/10.1016/j.diii.2018.12.003>. [Online]. Available: <https://www.sciencedirect.com/science/article/pii/S2211568418303218>
- [9] True-Anthem“How artificial intelligence can make publishing more profitable.” [Online]. Available: https://www.trueanthem.com/wp-content/uploads/2017/05/True_Anthem_Whitepaper_V1.pdf
- [10] Kim OK, Kim K“Artificial intelligence and publishing,” *Science Editing*, 2019, 6:89–90, DOI: 10.6087/KCSE.168. [Online]. Available: <http://www.escienceediting.org/journal/view.php?doi=10.6087/kcse.168>
- [11] Parisi N“Medical writing in the era of artificial intelligence.” [Online]. Available: <https://journal.emwa.org/artificial-intelligence-and-digital-health/medical-writing-in-the-era-of-artificial-intelligence/>
- [12] Extance A“How AI technology can tame the scientific literature,” *Nature*, 2018, 561:273–274, DOI: 10.1038/D41586-018-06617-5, PMID: 30202054.
- [13] G2-Research“Best AI Writing Assistants in 2023: Compare Reviews on 130+.” [Online]. Available: <https://www.g2.com/categories/ai-writing-assistant>
- [14] Gain A, Rao M, Bhat SK“Usage of grammarly – Online grammar and spelling checker tool at the health sciences Library, Manipal Academy of Higher Education, Manipal: A study,” *Library Philosophy and Practice*, 2019.
- [15] “Product Features | ProWritingAid.” [Online]. Available: <https://prowritingaid.com/features>
- [16] Nguyen T, Nguyen DH, Tran N et al.“Prolonged Coronary Transit Time and Reversed Flow Causing Functional Ischemia, Chest Pain and Syncope in Patients with Aortic Stenosis and Patent Coronary Arteries: An Angiographic and Machine Learning Analysis,” *TTU Journal of Biomedical Sciences*, 2022, 1:29–33, DOI: 10.53901/tjbs.2022.10.art05. [Online]. Available: <http://tjbs.ttuscience.org/index.php/tjbs/article/view/5>
- [17] Nguyen T, Nguyen HQ, Phan PD et al.“Questions on the Genesis and Growth of Coronary Lesions and their Answers Based on Fluid Mechanics Engineering: A New Dynamic Angiography Analysis,” *TTU Journal of Biomedical Sciences*, 2022, 1:1–11, DOI: 10.53901/tjbs.2022.10.art01. [Online]. Available: <http://tjbs.ttuscience.org/index.php/tjbs/article/view/8>
- [18] Pham HN, Tran N, Carver C et al.“Potential Causes of Sudden Cardiac Arrest in a Patient with COVID-19.” Mar. 2023.
- [19] Nguyen L, Le C, Pham S et al.“Significant bradycardia in patient with COVID-19 sepsis: Full management review,” *Case Reports in Internal Medicine*, Sep. 2021, 8:17, DOI: 10.5430/crim.v8n1p17. [Online]. Available: <https://www.sciedupress.com/journal/index.php/crim/article/view/20720>
- [20] Nguyen T, Do H, Pham T et al.“Left ventricular dysfunction causing ischemia in patients with patent coronary arteries,” *Perfusion*, 2018, 33:115–122, DOI: 10.1177/0267659117727826. [Online]. Available: <https://doi.org/10.1177/0267659117727826>